

Courtesy

Deutsches Herzzentrum
Berlin, Germany
S. Yilmaz, Dr. P. Ewert and Prof. F.
Berger Department of Congenital
Heart Disease, Pediatric Cardiology.

Symptoms

To evaluate the pulmonary vasculature before completion of a total cavo-pulmonary connection (TCPC), also known as the Fontan procedure. Due to age and size of the patient, minimum amount of x-ray and contrast dose should be used as much as possible.

Patient history

A 3 year old female patient of 13.5 kg, with tricuspid artresia. Earlier in life she underwent a Rashkind procedure, received an arterio-pulmonary (AP) shunt and later a bidirectional Glenn-anastomosis.

System information

Allura Xper FD10/10, Rotational angiography and Allura 3D-RA.

Findings

Allura 3D-RA image revealed a slight narrowing in the left pulmonary artery (LPA) caused by the semicircular indentation of the ascending aorta, which runs next to the LPA and the anastomosis.

Conclusion

With the finding of the LPA stenosis, caused by the ascending aorta, it was decided not to stent the LPA. The Allura 3D-RA helped to visualize the critical information with less x-ray dose and contrast. Without this technique, additional 2D x-ray acquisitions would have been required to come to the final conclusion.

Congenital Heart

Diagnosis of the pulmonary arteries before Fontan procedure facilitated by using Allura 3D-RA

Background

S. Yilmaz, Dr. P. Ewert, Prof. F. Berger
Department of Congenital Heart Disease,
Deutsches Herzzentrum Berlin, Berlin,
Germany

The German Heart Institute Berlin (DHZB) is a hospital noted for its treatment of cardiac, thoracic and vascular disease, artificial heart implantations and transplantations of the heart and lungs. At DHZB, about 3,500 open heart surgeries are performed annually and more than 1,000 other heart and blood vessel operations are carried out. This includes approximately 100 heart and/or lung transplants and 500 heart operations in premature infants, neonates, infants and children. DHZB also performs around 200 diagnostic and 450 therapeutic intervention procedures for congenital and acquired heart diseases per year.

Case

A 3 year old female patient of 13.5 kg, with tricuspid artresia, was brought to the cathlab for diagnosis and evaluation before completion of a total cavo-pulmonary connection (TCPC), also known as the Fontan procedure. Earlier in life she underwent a Rashkind procedure, received an arterio-pulmonary (AP) shunt and later a bidirectional Glenn-anastomosis.

Clinical challenge

Evaluate the pulmonary vasculature before

completion of the Fontan procedure, with the minimum amount of x-ray and contrast dose as possible. Using standard angiogram, it would require 3 acquisitions to have a complete evaluation.

Solution

Allura 3D-RA was used to provide a better visualisation of the 3D anatomy of the aorta, which subsequently helped to support the course of treatment strategy. It is also used by the clinician for better insight to plan the optimal therapeutic approach. The Allura 3D-RA provides detailed 3D visualisation of the pulmonary vasculature and anastomosis from any angulation and rotation. It can be used as a tool to help in selecting the optimal projection to view the area of interest. In this case, it was beneficial for diagnosis and treatment planning.

Method and materials used

An Allura 3D-RA acquisition was made for a detailed 3D visualisation of the pulmonary arteries.
X-ray system: Allura Xper FD10/10
Acquisition protocol: A 4 sec, 240 degree (120 LAO - 120 RAO), rotational angiogram at 30 frames/sec at 25 cm field of view.
Material: we injected contrast of total 30 ml at 5 ml/s in the Glenn-anastomosis using an injector, with an injection delay of 2 s before acquisition. The contrast was diluted 1:2 saline, which resulted of an actual contrast load of 10 ml.

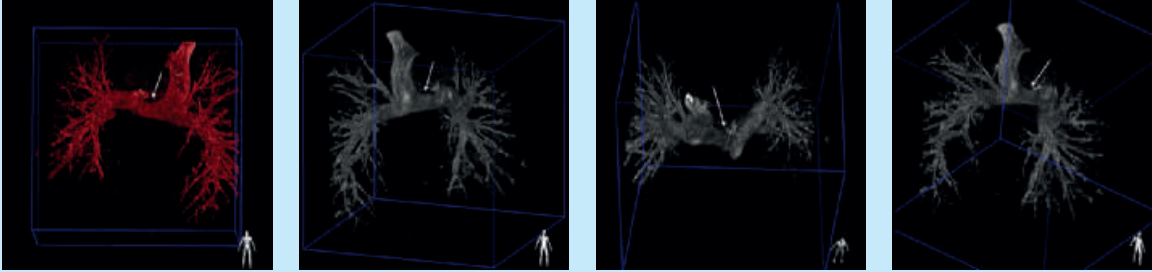


Figure 1: 3D reconstruction of the pulmonary arteries and Glenn anastomosis. The restriction in the LPA is caused by the ascending aorta, which runs next to the LPA and the anastomosis.

During the whole procedure the patient was sedated, while maintaining normal respiration. The 3D reconstructed data was displayed almost instantaneously after end of acquisition.

Results

The Allura 3D-RA reconstructed image facilitated a detailed visualization of the pulmonary vasculature and the anastomosis revealing a slight narrowing in the left pulmonary artery (LPA) caused by the semicircular indentation of the ascending aorta, which runs next to the LPA and the anastomosis (Figure 1).

Conclusion

The Left Pulmonary Artery (LPA) restriction was clearly visible from the Allura 3D-RA images. With the finding of the LPA stenosis, caused by the ascending aorta, it was decided not to stent the LPA.

Without performing the 3D acquisition and reconstruction, additional 2D x-ray acquisitions would have been required to support the final diagnosis.

The Allura 3D-RA helped in this case to support the final diagnosis with less x-ray radiation and contrast media.

Comments from Professor Berger

Prof. Dr. med. Felix Berger,
Director



Probably the biggest advantage of three-dimensional rotational angiography is that with one shot, during one acquisition, you have the opportunity to judge what will be the best projection to go forward with the interventional procedure or with the diagnostic analysis of the anatomy.

Sometimes, especially in the low pressure physiology of a pre-Fontan situation, the hemodynamic significance of a narrowing (indentation) is due to the exact morphology of that which you are looking to visualize. You need an optimal view of the indentation to support a decision whether it is significant or not. With the three-dimensional reconstruction, we had the opportunity to get this view in one single shot. We reconstructed this morphological narrowing and saw that it was not significant enough to put in a stent before we proceeded with the Fontan operation in this patient.

Deutsches Herzzentrum Berlin



Please visit www.philips.com/3DRA



© 2011 Koninklijke Philips Electronics N.V.
All rights are reserved.

Philips Healthcare reserves the right to make changes in specifications and/or to discontinue any product at any time without notice or obligation and will not be liable for any consequences resulting from the use of this publication.

Philips Healthcare is part of Royal Philips Electronics

www.philips.com/healthcare
healthcare@philips.com

Printed in The Netherlands
4522 962 67711 * JUL 2011